

## IMAGING OF THE MEAN FREQUENCY OF THE ULTRASONIC ECHOES

Ziemowit KLIMONDA, Andrzej NOWICKI

Institute of Fundamental Technological Research  
Polish Academy of Sciences  
Świętokrzyska 21, 00-049 Warszawa, Poland  
e-mail: zklim@ippt.gov.pl

*(received July 15, 2007; accepted October 18, 2007)*

A standard USG image is in fact a visualization of a distribution of the reflexion coefficients. There is an increasing interest in imaging of the different parameters, which might characterize another physical properties of a tissue. The attenuation coefficient is one of such parameters and theoretically it can be estimated using frequency shift of the RF signal. The frequency shift results from dispersive character of the attenuation in tissue and is a function of attenuation along the propagate path. In this work authors use echo's mean frequency as an imaging modality. The results of measurement of tissue phantom using 10 MHz linear array are presented. The preliminary results are encouraging being the first attempt towards mapping of the attenuation in tissue.

**Keywords:** parametric visualization, mean frequency, attenuation estimation.

### 1. Introduction

A standard USG image is in fact a reflexion coefficient map of the visualized region in tissue. Mapping of another parameters, such as backscattering, speed of sound, or attenuation could be interesting from diagnostic point of view, because these are strictly connected with internal tissue structure. The attenuation coefficient is increasing with frequency, so it could be estimated by measuring the changes in a spectrum of RF signals. Unfortunately in vivo test shows large variability of attenuation coefficient estimated by such method. This seems to be strong restriction of visualisation of attenuation maps in tissue. On the other hand, an information on echo's mean frequency differs from the one carried by the echo envelope. This is a strong motivation in looking for the efficient method of unambiguous attenuation estimator to be used in US imaging. In this work, the specific conditions of the local frequency measurements applied for imaging, will be discussed.

## 2. Theory

The instantaneous frequency is defined as a

$$f_{\text{inst}} = \frac{1}{2\pi} \frac{d\phi}{dt}, \quad (1)$$

where  $\phi$  is a phase of a signal, and  $t$  is a time. There are couple of method suitable for estimation of instantaneous frequency, e.g. mean frequency (first moment of spectrum) or zero-crossing (second moment of spectrum). In this work we investigate the correlation based frequency estimator, which is often used in Doppler instruments [1]. The phase of a signal is equal to

$$\phi(t) = \arctan \left[ \frac{Q(t)}{I(t)} \right], \quad (2)$$

where  $I(t)$  is the real part of the echo signal, and  $Q(t)$  is its imaginary part and which is equal to the Hilbert transform of  $I(t)$ . In reality the echo signals are processed in digitized, sampled form, so differentials can be replaces by the differences and the mean frequency of the echo signal can be express as,

$$f_{\text{mean}} = \frac{1}{2\pi T} \arctan \left[ \frac{\sum_{i=1}^N [Q_i I_{i-t} - Q_{i-t} I_i]}{\sum_{i=1}^N [I_i I_{i-t} + Q_{i-t} Q_i]} \right], \quad (3)$$

where  $T$  is a sampling period and  $N$  is a window width [2]. Indices  $i$  and  $(i-1)$  correspond to the actual and previous value of the signal sample recorded with the sampling frequency  $f_s = 1/T$ .

## 3. Measurements

The measurements were done using the US Acuson Antares scanner (Siemens Medical Solutions USA, Inc.) and the tissue phantom RMI405GSX (Gammex rmi, Inc.). The scanner was equipped with the 10 MHz linear array VF13-5 and Axius Direct Ultrasound Research Interface which is a dedicated module enabling the recording of raw RF lines. Three different anechoic targets (2, 4, and 6 mm in diameter) were located in the phantom at 3.5 cm depth. After recording the RF scan lines, they were processed offline in order to estimate the local frequency of an echo signal according to Eq. (3).

The window width ( $N$ ) included 64 samples corresponding to about 2.5 mm depth. In Fig. 1 standard B-scan (a) and frequency mapping (b) are presented. The contrast between cystic targets and the background is evidently better in frequency mapping image. It is clearly visible in the Fig. 2, where normalized envelope (a) and local frequency from singular RF line (b) are compared. The data correspond to the beam passing through the biggest cyst. On the other hand the echoic object placed at 2.5 cm depth, in the middle of the image, is less visible in frequency image comparing to the standard




Fig. 1. B-mode scan (a), and frequency mapping (b) of the tissue phantom.

B-mode scan (Fig. 3). The frequency line have decreasing trend, which comes from attenuation. The attenuation coefficient is an increasing and linear function of the frequency for soft tissue [2] and for the phantom as well so the starting value of frequency line should correspond to the mean frequency of the transmitted burst equal to 10 MHz. In Figs. 2b and 3b frequency lines start from much lower level and next increase sharply over about 0.5 cm path, and then start to decrease slowly. This effect probably rise from near field structure in direct neighbourhood of transducer. The strong fluctuations of local frequency are visible, which are in agreement with earlier reports [3–5].

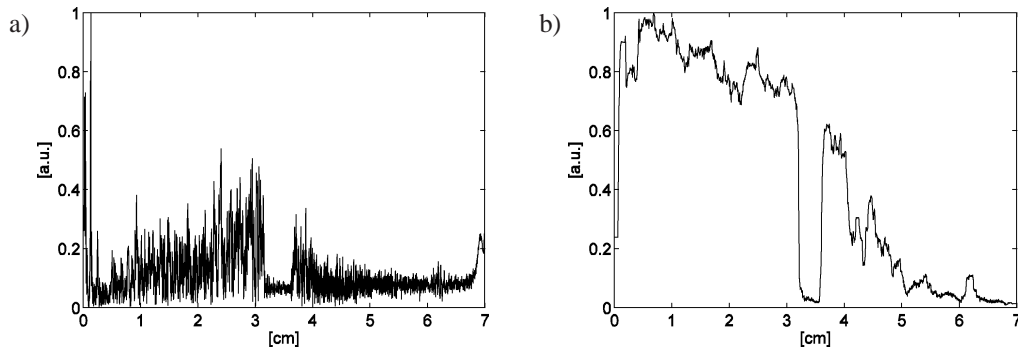


Fig. 2. Normalised envelope of RF line through the biggest cystic object at 3.5 cm depth (a), and appropriate frequency mapping (b).

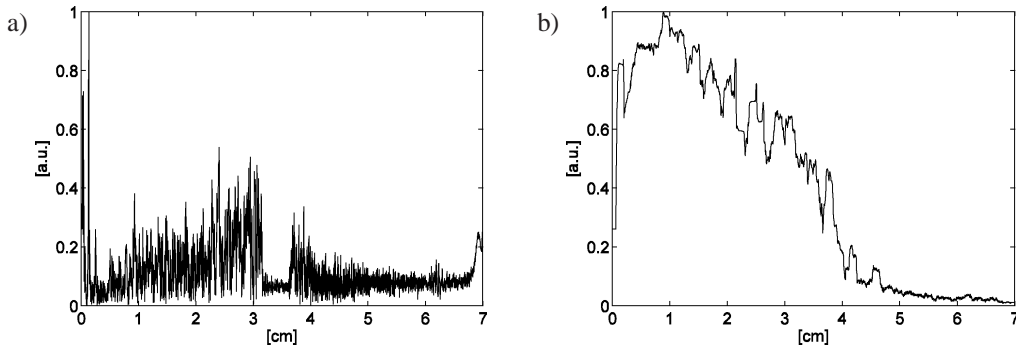


Fig. 3. Normalized envelope of RF line through the echoic object at 2.5 cm depth (a), and appropriate frequency mapping (b).

It should be noticed the sudden drop of the mean frequency at the cystic object area, and subsequent return to the decreasing trend (Fig. 2). The main reason of this behaviour results from the anechoic character of the cyst mimicking object. Within the boundary of the cyst, there is no sufficient backscattered signal to be used efficiently in the algorithm described by the Eq. (3) and the apparent centroid is not measured – the resulting value is zero. This is also the subject of better contrast between speckle like background, where scattering objects are presented, and cyst, where there are no scatterers.

#### 4. Conclusions

The acquired results show, that simple estimation of the local mean frequency of RF-line could be useful as a medical image modality in specific conditions or for specific targets, such as anechoic cyst. In addition frequency data give possibility to better estimate total attenuation along the pulse path. The data obtained using frequency estimator could supplement the standard reflexion coefficient data, but can not replace it, as was shown in Fig. 3. The direct evaluation of attenuation coefficient from frequency data, is hard to succeed due to strong fluctuations of the central frequency estimation, so the more robust model should be developed.

#### References

- [1] NOWICKI A., *Diagnostyka ultradźwiękowa. Podstawy fizyczne ultrasonografii i metod dopplerowskich*, MAKmed, 2000.
- [2] NOWICKI A., *Podstawy Ultrasonografii Dopplerowskiej*, PWN, Warszawa 1995.
- [3] GARRA B. S., SHAWKER T. H., NASSI M., RUSSELL M. A., *Ultrasound attenuation measurements of the liver in-vivo using a commercial sector scanner*, *Ultrasound Imag.*, **6**, 396–407 (1984).
- [4] OPHIR J., GHOUSE M. A., FERRARI L. A., *Attenuation estimation with the zero crossing technique: phantom studies*, *Ultrasound Imag.*, **7**, 122–132 (1985).
- [5] SHUNG K. K., THIEME G. A. [Eds.], *Ultrasonic Scattering in Biological Tissues*, CRC Press, Inc., 1993.